

PATIENT

Buddy Aloisi

SPECIES

Canine

BREED

Poodle Mix

SEX

Male Neutered

AGE

13 years

WEIGHT

24.8lbs

INTERPRETED BY

Maggie Machen Lamy, DVM DACVIM (Cardiology)

IMAGING PERFORMED BY

Pamela Harrigan, RDCS

HOSPITAL NAME

Mass Veterinary Services

REFERRING VET

Dr. Masloski

INVOICE

22987

DATE

3/8/22

PRESENTING CLINICAL SIGNS

History: Recheck echo. History chronic valvular disease - Stage B1. Current presentation: Buddy has good and bad days with his breathing. Is reluctant to do stairs. Good appetite and his activity level has remained normal. On auscultation: NSR, grade III/VI murmur with PMI left apical area, PSS, lung fields clear; collapsing tracheal cough throughout exam. BP: 160mmHg -Current medications: 1) Temaril p 1 tab twice a day 2) Hycodan/hydrocodone with homatropine 5mg 1.5 tabs twice a day 3) Thyroxine 0.1mg 1 tab twice a day 4) Lasix/furosemide 12.5mg 1 tab twice a day *No sedation. -Pertinent previous echo findings (7/14/21 MML): LA 2.1 cm; LA:Ao 1.5; LV 2.8 cm; mild LAE; mild MR; trivial TR.

ECHOCARDIOGRAM FINDINGS

2D, m-mode, color flow and Doppler imaging is available. **Left ventricle:** The LV diameter is normal with adequate myocardial function. LV wall thicknesses are normal. **Left atrium:** The left atrium is minimally dilated. **Mitral valve:** The mitral valve is mildly thickened with no prolapse into the left atrial lumen. Trace mitral regurgitation. **Aortic valve/aorta:** The aortic valve is normal in morphology and mobility. Normal aortic outflow velocity; laminar flow. No aortic insufficiency. **Right ventricle:** Normal right ventricular diameter and morphology indicating no overt evidence of pulmonary arterial hypertension. **Right atrium:** Normal RA dimension. **Tricuspid valve:** The tricuspid valve appears normal with no tricuspid regurgitation. **Pulmonic valve/pulmonary artery:** The pulmonic valve is normal in morphology and mobility. No pulmonic insufficiency. Normal RVOT velocity; laminar flow. **Pericardium/other:** No pericardial or pleural effusion noted. No obvious cardiac masses. **Heart rhythm:** ECG reveals a sinus rhythm with an average HR of 100bpm.

2-Dimensional Measurements

Ao diam (cm)	1.6
LA diam (cm)	2.3
LA:Ao (Swe)	1.4
IVS thickness (cm)	0.7
LVID diastole (cm)	2.9
PW thickness (cm)	0.7
LVID systole (cm)	1.0
FS (%)	66

Doppler Measurements

PV Vmax (m/s)	1.3
AoV Vmax (m/s)	1.6
MR Vmax (m/s)	NM
TR Vmax (m/s)	NA
TR PG (mmHg)	NA

INTERPRETATION OF THE FINDINGS

Chronic degenerative valve disease persists with remarkably stable disease. The mitral leak is difficult to see in this study; however, the valve remains thickened. The left atrial dimension is unchanged, and no additional issues are identified.

These findings suggest the respiratory changes remain noncardiac in origin. No indication to continue Lasix in this patient as was previously discussed. Consider further respiratory work-up/treatment (more aggressive hydrocodone, taper course of steroids, Enrofloxacin, TTW/BAL, etc.).

Continued assessment of progression in the future will help predict long term prognosis, which is highly variable at this stage (B1).



PATIENT

Buddy Aloisi

SPECIES

Canine

BREED

Poodle Mix

SEX

Male Neutered

AGE

13 years

WEIGHT

24.8lbs

INTERPRETED BY

Maggie Machen Lamy, DVM
DACVIM (Cardiology)

IMAGING PERFORMED BY

Pamela Harrigan, RDCS

HOSPITAL NAME

Mass Veterinary Services

REFERRING VET

Dr. Masloski

INVOICE

22987

DATE

3/8/22

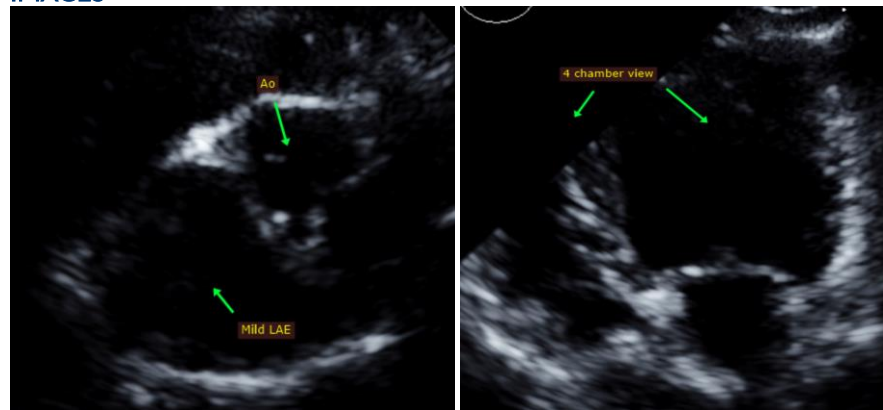
RECOMMENDATIONS

- No cardiac medications are clearly indicated.
- Discontinue Lasix as discussed.
- Further respiratory work up/treatment as discussed.
- Omega fatty acid supplementation and mild salt restriction may be of some long-term benefit.
- Anesthetic risk is considered mild if needed. Cardiac protective drug choices (opioid/benzodiazepine premedication, propofol or alfaxalone induction, isoflurane gas) are recommended. Pre-oxygenate for 5-10 minutes prior to induction. Monitor for arrhythmias, hypotension, and hypoxia both intra and post-operatively and intervene as necessary. Mild IV fluid restriction is recommended to avoid fluid overload. Avoid heart rate stimulating drugs such as atropine unless clinically indicated.
- Monitor for development of a cough, labored breathing, exercise intolerance or collapse episodes.

PLAN

- Recommend conservative monitoring with a recheck echocardiogram in 6-12 months, sooner if any development of clinical signs.

IMAGES



The information and recommendations provided are based on the images presented by the referring veterinarian. No evaluation can be communicated regarding pathology that was not visible in the image/video clips provided.

Thank you for this referral. This report was generated using transcription software, and minor dictation errors may be present. If the clinical or image interpretation does not parallel your findings or if I can be of any further assistance, please contact me.

Maggie Machen Lamy, DVM
Diplomate of the American College of Veterinary Internal Medicine (Cardiology)
info@sonopath.com

Echocardiogram performed by: Pamela Harrigan, RDCS
Pet Animal Ultrasound Service (4paus.com)